

A Prospective Study of Functional Outcome of Total Hip Replacement in Degenerative Arthritis



Orthopaedic

KEYWORDS : Uncemented Total Hip Replacement ; Modified Harris hip score ; Osteoarthritis

Dr.RAFEEQ M.D.

post graduate in Sanjay Gandhi Institute of Trauma and Orthopaedics,Bengaluru-560011

Dr.T.H.Prakashappa

D.ortho ,M S ortho. Professor Department of orthopaedics, Sanjay Gandhi Institute Of Trauma & Orthopaedics,Bengaluru-560011

Dr H S Chandrashekar

D.ortho, M S Ortho. Professor & HOD Sanjay Gandhi Institute Of Trauma & Orthopaedics,Bengaluru-560011

ABSTRACT

A prospective study conducted on 39 hips of 30 degenerative arthritis patients with mean age of 39years(range 20-70yrs) who underwent uncemented total hip replacement performed in the Department of Orthopaedics, Sanjay Gandhi Institute of Trauma and Orthopaedics ,Bangalore during 18months period from November 2014 to April 2016. In our study, 70% were males & 30% females . 85% patients had secondary osteoarthritis and 15% had primary osteoarthritis of hip.Mean follow up was 10.13months (3-16 months) . Functional evaluation using modified harris hip score showed excellent results in 97% hips and good results in 3% hips. 10% of patients had complications. In Conclusion, the current generation of uncemented prosthesis used in the total hip replacement for degenerative arthritis of hip , provides satisfactory clinical and radiographical outcomes after a short duration of follow up. Even though the study was not free of complications, the overall functional and radiological outcome showed excellent results.

INTRODUCTION

Total hip replacement (THR) is the most commonly performed adult reconstructive hip procedure.

The most common condition for which THR is done is severe osteoarthritis(OA) , also called degenerative arthritis of hip, accounting for 70% of cases¹. Other causes for secondary osteoarthritis include developmental, post traumatic and connective tissue disorders. The primary indication for this procedure is severe pain and the limitation in activities of daily living that it causes. To warrant doing Total hip replacement, pain must be refractory to conservative measures such as oral nonsteroidal anti-inflammatory medication, weight reduction, activity restriction, and the use of supports such as a cane².

OA is a common and progressive joint disease causing pain, reduced physical function and reduced quality of life. Total hip replacement (THR) provides pain reduction and improves physical function and quality of life in most patients with end-stage hipOA.³

MATERIAL & METHODS

This is a prospective study conducted in the Department of Orthopaedics, Sanjay Gandhi Institute of Trauma and Orthopaedics ,Bangalore during 18months period from November 2014 to April 2016. The clearance from institutional ethical committee was obtained before starting the study.

Inclusion criteria included patients of age more than 20yrs & above and of either sex with chronic symptoms of degenerative arthritis of hip not responding to at least six months of conservative treatment with analgesics, and physiotherapy which affects their activities of daily living.

Exclusion criteria included patients below the age of 20 years , who are unfit for surgery due to associated medical problems and presence of active foci of infection in the body.

A total of 30 patients with 39 hips , who had given an informed and written consent for total hip replacement surgery were included in to the study.

Patients were admitted and examined according to protocol both clinically and radiologically, and functional outcome was assessed by modified Harris hip score both preoperatively and postoperatively.

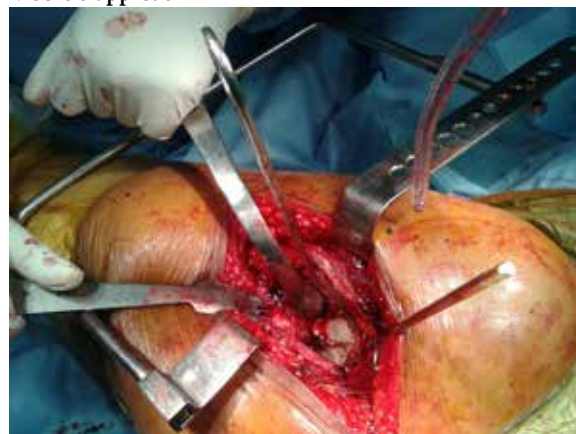All patients were operated upon for Total Hip Arthroplasty under combined spinal epidural anaesthesia by posterior(moore's) approach using uncemented acetabular cup and uncemented femoral stem.The patients are reviewed with post op x-rays immediately after surgery and at the end of 6, 12, 24 weeks after the surgery.

Post operatively limb is kept in abduction with pillow between two lower limbs.

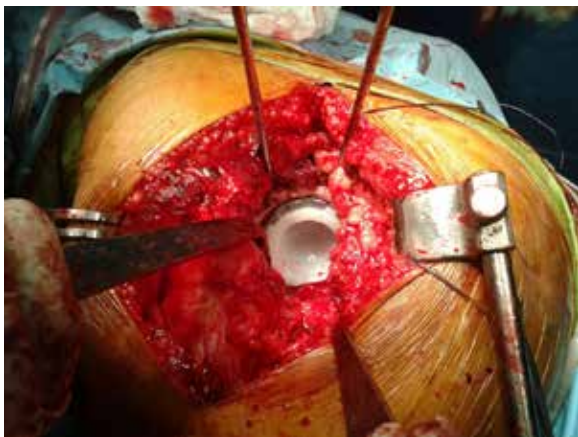
Static quadriceps exercises, knee and ankle exercises done and patients were ambulated from first postoperative day itself. DVT prophylaxis with inj enoxheparin 40mg sc OD for 3 days and oral anticoagulants(ecospirin 150mg OD) continued for 1 month.Patients were advised not to squat/ sit cross legged/ not to cross the lower limb across the midline and not to use Indian toilets.

OPERATIVE PHOTOS

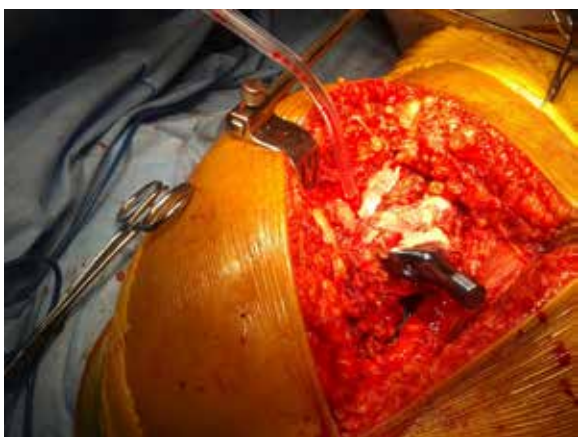Moore's approach



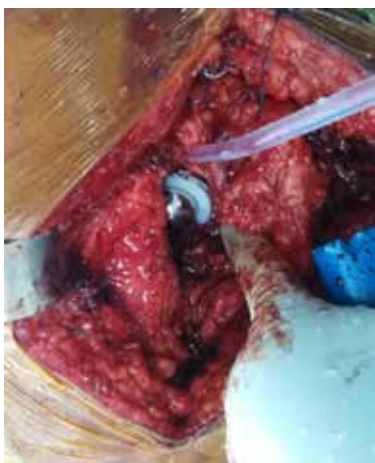
Acetabular Cup with liner insertion



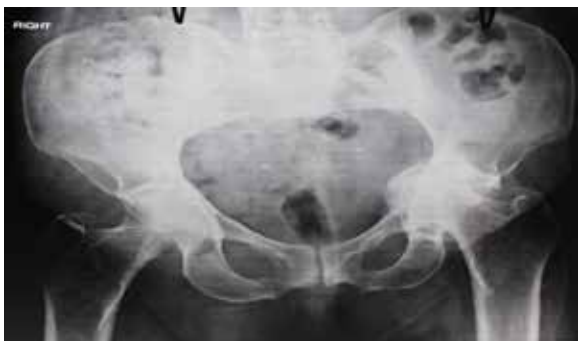Femoral stem insertion



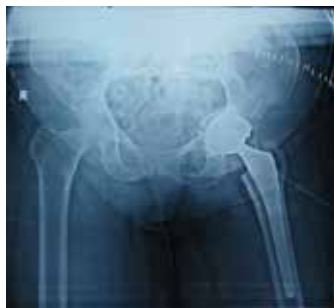Femoral head insertion and reduction



Preoperative X ray

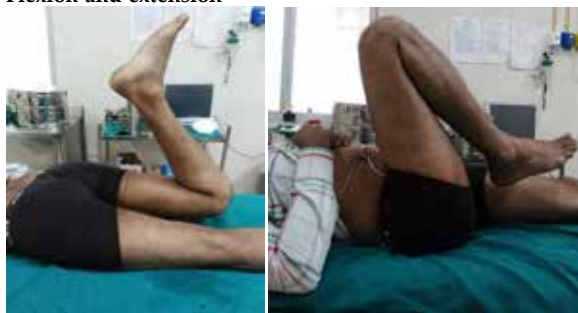

Postoperative X ray

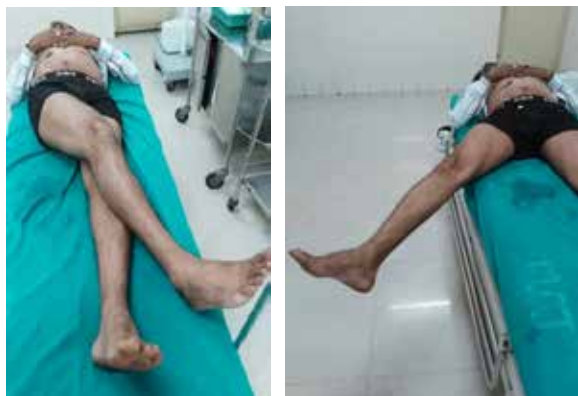

Postoperative range of motion

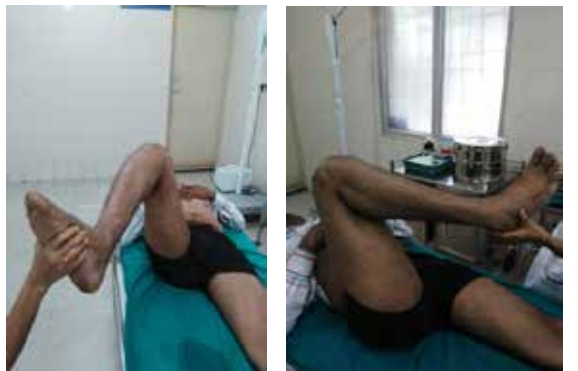Flexion and extension



Adduction and abduction



Internal and external rotation



RESULTS

39 hips were operated upon 30 patients for degenerative arthritis of hip. Mean age was 39 years (range 20-70 years). 21 (70%) were males and 9 (30%) were females.

Among 30 patients, 9 bilateral (30%), 11 on right side (36.67%) and 9 on left side (33.33%) was affected. 21 patients underwent unilateral THR. 9 patients underwent staged bilateral THR at an interval of 6 weeks.

The main indication for surgery was secondary OA in 33cases/hips (85%) in which most commonly it was due to AVN (26 cases, 66.67%) followed by trauma (4 cases, 10.26%) and perthes (3cases, 7.69%) .In the remaining 6 cases/hips , it was due to primary OA (15%).

The minimum patient follow up for the study was 3 months and the maximum was 16 months. The mean follow up was for 10.13 months

Mean preoperative Harris hip score was 39.7, ranging from 30 to 54. This score improved to 88.04 immediate post operative and 94 (86-97) at latest follow up (Table 1).

(Excellent 90 to100 score, Good - 80 to 90, Fair 70 to 79 points, Poor - below 70)

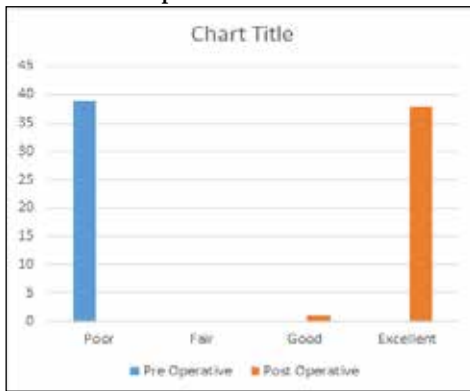Table1- Modified Harris hip score results

Mean SD	Pre Op HHS	Post Op HHS	T value	P value
Pain	12.30 4.26	43.48 1.35	38.21	<0.05
Function	25.15 5.25	41.64 1.67	16.39	<0.05
Absence of deformity	0.30 1.07	4	18.93	<0.05
ROM score	2.17 0.91	4.89 0.30	30.28	<0.05
Total score	39.61 06.71	93.97 02.33	41.91	<0.05

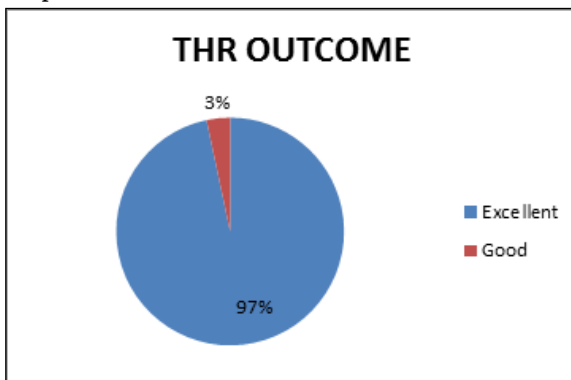
The results showed a significant improvement (mean 94), where in 29 patients had an excellent score , 1 had good score(Graph 1).

The outcome after total hip replacement was excellent in 97% and good in 3% of the study group(Graph 2).

Graph1- clustered bar graph - Preoperative and postoperative harris hip score

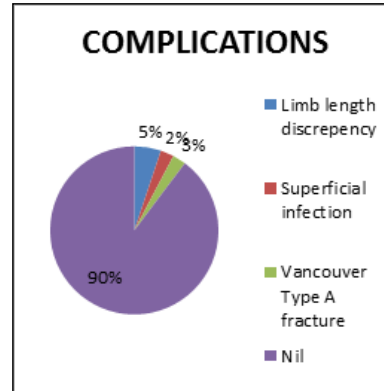


Graph 2 – THR outcome



In our study 89.74%(35) of the cases had no complications.

10.26% (4) of cases had complications which included LLD(2cases,5%) , superficial infection(1case,2.56%) which resolved 2 weeks postoperatively and Vancouver type A periprosthetic femur fracture(1 case,2.56%) involving lesser trochanter, treated conservatively and went on to union (Graph 3).



Graph 3 – complications

At the latest follow-up none of the acetabular and femoral components showed the evidence of osteolysis and loosening. The femoral stem was in neutral position in 36 cases(92.31%) and varus in position in 3 cases(7.69%) .

DISCUSSION

This study was carried out on 39 hips in 30 patients who underwent uncemented THR.

In our study, patients age group ranged from 20-70 years , out of which 7 (23.33%) were below 30 years, 8 (26.67%) between 30-39 years , 9 (30%) were between 40-49yrs. The mean age was 42.44years , 3 (10%) were between 50-59yrs and 3(10%) were more than 60 years. The median age was 39years.

21 (70%) were males and 9 (30%) females.

11 patients(36.67%) were operated on right side, 10patients(33.33%)on left side and 9patients(30%) had bilateral replacements.

The main indication for surgery was secondary OA in 33hips (85%) in which most commonly it was due to AVN (26 hips, 66.67%) followed by trauma (4 hips, 10.26%) and perthes (3hips, 7.69%) .In the remaining 6 hips , it was due to primary OA (15%) as compared to primary osteoarthritis as the most common indication in Western studies (et al 42%, et al 58% and Berger⁶ et al 77%).The above facts suggest the high rate of AVN and low rate of primary osteoarthritis in Indian patients.

All surgeries were performed in conventional operation theatre through posterior approach .

Uncemented press fit tapered stem-plasma coated was used in all patients. The stem size ranged from 9-14 and most commonly used was 12(48.71%).

The head made of cobalt chrome alloy , size ranged from 28-36 and most commonly used was 32(64.10%).

Press fit- plasma coated actabular shell was used in all cases. The maximum shell size used was 56 and minimum was 48. Shell size 52 was the most commonly used (41.02%) .

UHMWPE liner was used corresponding to the size of the head used.

Size 32 was most frequently used (25hips, 64.10%).

The follow up ranged from a minimum of 3 mths to maximum of 16 months (mean 10.03 months) at regular intervals – 6weeks, 3months, 6months, 12months, and a maximum of 16month . All patients were evaluated by the Modified Harris hip score .

Mean Harris hip score improved from 39.70 to 88.04 immediate postoperatively and 94 at latest follow up, as compared to et al study (from 55.3 to 91) , et al (from 48 to 93) , et al (from 42 to 84), and et al (from 43 to 92), et al (average score of 93 at minimum 5 year follow-up), et al (from 51 to 94).

A hip is graded as excellent for 90 to 100 points; good for 80 to 89 points; fair for 71-79 points; poor for 70 points and below. We had excellent results in 38hips(97%), good in 1(3%) as comparable to et al (75 % excellent , 19 % good and 7% fair at the end of 2 years); et al (84% Excellent,7% Good and 3% Poor) ; et al (87% Excellent,7% Fair and 6% Poor) .

All patients didn't require support for walking at the end of study. Our results are comparable with et al.(88% needed no support, 10% needed crutches), (no patients used support).

89.74%(35) of the cases had no complications.10.26% (4) of cases had complications which included LLD(2cases,5%),superficial infection (1case,2.56%) and Vancouver type A periprosthetic femur fracture(1 case,2.56%).

Postoperative LLD was not seen in 94.86% of the study group. About 5.14%(2 cases) of the study group had LLD of 1 cm and 1.5cm. The results are comparable with studies by (LLD of 1 to 1.8 cm).

1 patient(2.56%) had Vancouver type A periprosthetic femur fracture (undisplaced) involving lesser trochanter during procedure. Later on it was united. Our results are comparable with Berry et al¹⁴ (5.4% of periprosthetic femur fractures) , et al (0.89%) and et al (4.3%) .

1 patient(2.56%) had **superficial infection** ,culture was negative and wound healed completely 2 weeks postoperatively. Our results are comparable with et al (1.1%), SF et al (0.38%) .

At latest follow-up, femoral stem was in neutral position in 36 cases(92.31%) and varus in position in 3 cases(7.69%) . no radiograph showed any evidence of new radiolucency or any shift in position of the femoral and acetabular components. Stress shielding was noted in 2 patients.

CONCLUSION

Degenerative arthritis of hip has debilitated many patients. Secondary degenerative arthritis is more common than primary degenerative arthritis and has affected mainly people of younger age group.

The outcome of the total hip replacement in degenerative arthritis of hip joint is determined by many factors including the design of component, the selection of the

patients, and the operative technique. The results of the procedure needs long term studies for evaluating the complete effect.

We have evaluated Total hip arthroplasty, using uncemented prosthesis. Our study suggests that the current generation of uncemented prosthesis used in the total hip replacement for degenerative arthritis of hip , provides satisfactory clinical and radiographical outcomes after a short duration of follow up. Even though the study was not free of complications, the overall functional and radiological outcome showed excellent results.

REFERENCES

1. Siopack JS, Jergesen HE: Total hip arthroplasty. *West J Med* 1995;162:243-249
2. Title : Campbell's operative orthopaedics , chapter 3, Arthroplasty of hip , James W. Harkes, John R. Crockarell 12th edn
3. Signe Rosenlund, Leif Broeng, Carsten Jensen, Anders Holsgaard-Larsen et al . The effect of posterior and lateral approach on patient-reported outcome measures and physical function in patients with osteoarthritis, undergoing total hip replacement:
4. .D.Owen., C.G.Moran., S.R.Smith. Results of uncemented porous coated anatomic total hip replacement' *J Bone Joint Surg (Br)* 1994;76-B:258-62.
5. Jeffrey.R.McLaughlin., Kyla. R. Lee. Total hip arthroplasty with an uncemented femoral component. *J Bone Joint Surg (Br)* 1997;79-B:900-7.
6. Berger.R.A. Primary cementless acetabular reconstruction in patients younger than 50 years old. *Clin Orthop*.1997; 249:216-226.
7. Y.H. Kim., Vana.E.M.Kim. Uncemented porous coated anatomic total hip replacement *J Bone Joint Surg (Br)* 1993;75-B:6-14.
8. Katz.R.L., Bourne.R.B., Rorabeck.C.H. and Mc Gee.H. Total hip arthroplasty in patients with avascular necrosis of hip. Follow up observations on cementless and cemented operations. *Clin Orthop*.1992;281:145-151.
9. Mont.M.A., Maar.D.C., Krackow.K.A., Jacobs.M.A., Jones.L.C. and Hungerford, D.S. Total hip replacement without cement for non-inflammatory osteoarthritis in patients who are less than forty-five years old. *J. Bone and Joint Surg* 1993;75-A:740-751.
10. Heekin.R.D., Callaghan.J.J., Hopkinson,W.J., Savory.C.G. and Xenos,J.S. The porous coated anatomic Total hip prosthesis, inserted without cement-Results after 5-7 years in prospective study. *J Bone Joint Surg* 1993;75-A:77-91.
11. Archibeck M.J., Berger R.A., Jacobs J.J., Quigley L.R., Gitelis.S., Rosenberg.A.G., Galante.J.O.; Second generation cementless total hip arthroplasty. 8-11 year results. *J Bone Joint Surgery Am*.2001Nov; 83-A(11):1666-73.
12. Tian.J.Liang., Mu Z You, Pie F Xing, Shen Bin, Zhou Zhong Ke. Uncemented Total hip arthroplasty in patients younger than 50 years. April 2010 Vol33 Issue4. www.healio.com/orthopaedics/hip/ortho/uncemented total hip arthroplasty in patients younger than 50 years.
13. Ranawat CS, Rao RR, Rodriguez JA, et al.: Correction of limb-length inequality during total hip arthroplasty. *J Arthroplasty*. 16:715 2001 11547369
14. Daniel. J.Berry. Epidemiology-Hip and knee. *Orthopedic clinics of North America* Vol 30, issue 2, Apr 1999 pages 183-190.
15. Savin.L., Barhoarosie.C., Botez.P. Periprosthetic femoral fractures – evaluation of risk factors. *Rev Med Chir Soc Nat lasi*. 2012 Jul-Sep;116(3):846-52
16. Berend. K.R., Lombardi. A.V. Jr, Mallory.T.H., Chonko. D.J., Dodds.K.L., Adams J.B. Cerclage wires or cables for the management of intraoperative fracture associated with cementless tapered femoral prosthesis ; Results at 2 to 16 years. *J Arthroplasty* 2004;19(suppl 2):17-21.
17. Philips.C.B., Barret.J.A., Losina E, Mahomed.N.N., Lingard. E.A. Incidence rates of dislocation, pulmonary embolism and deep infection during first six months after elective total hip replacement. *J Bone Joint Surg Am*. 2003 Jan;85-A(1):20-6.
18. Schutzer. S.F, Harris.W.H. Deep wound infection after total hip replacement under contemporary aseptic conditions. *J Bone Joint Surg Am* 1988;70-A:724-7.